



**PATIENT**

Bella Triompo

**SPECIES**

Canine

**BREED**

Labrador Mix

**SEX**

Female Spayed

**AGE**

11 years

**WEIGHT**

71.2lbs

**PRESENTING CLINICAL SIGNS**

History: New grade II/VI heart murmur; no clinical signs. Echocardiogram prior anesthesia for mass removal. BP: 135mmHg.

**ECHOCARDIOGRAM FINDINGS**

2D, m-mode, color flow and Doppler imaging is available.

**Left ventricle:** The LV diameter is normal with adequate myocardial function. LV wall thicknesses are normal.

**Left atrium:** The left atrium is normal in dimension.

**Mitral valve:** The mitral valve is normal with no prolapse into the left atrial lumen. Trivial mitral regurgitation.

**Aortic valve/aorta:** The aortic valve is normal in morphology and mobility. Mildly elevated aortic outflow velocity; laminar flow. Mildly dilated aortic root. No aortic insufficiency.

**Right ventricle:** Normal right ventricular diameter and morphology indicating no overt evidence of pulmonary arterial hypertension.

**Right atrium:** Normal RA dimension.

**Tricuspid valve:** The tricuspid valve appears normal with no tricuspid regurgitation.

**Pulmonic valve/pulmonary artery:** The pulmonic valve is normal in morphology and mobility. No pulmonic insufficiency. Normal RVOT velocity; laminar flow.

**Pericardium/other:** No pericardial or pleural effusion noted. No obvious cardiac masses.

**Heart rhythm:** ECG reveals a sinus rhythm with an average HR of 160bpm.

**2-Dimensional Measurements**

Ao diam (cm)	2.9
LA diam (cm)	3.0
LA:Ao (Swe)	1.0
IVS thickness (cm)	1.0
LVID diastole (cm)	3.4
PW thickness (cm)	1.0
LVID systole (cm)	1.5
FS (%)	56

**Doppler Measurements**

PV Vmax (m/s)	1.1
AoV Vmax (m/s)	1.7
MR Vmax (m/s)	NA
TR Vmax (m/s)	NA
TR PG (mmHg)	NA

**INTERPRETED BY**

Maggie Machen  
Lamy, DVM  
DACVIM (Cardiology)

**IMAGING**

**PERFORMED BY**

Pamela Harrigan,  
RDCS

**HOSPITAL NAME**

Wignall Animal  
Hospital

**REFERRING VET**

Dr. Colella

**INVOICE**

25715

**DATE**

8/11/22

**INTERPRETATION OF THE FINDINGS**

The only cause of a murmur identified is increased flow velocity through the LVOT/aortic root. No obvious subaortic ridge or valvular abnormalities are visualized, and in the absence of structural abnormalities this is considered a benign flow murmur. If this is a new murmur, it is reasonable to monitor periodically via recheck echocardiography in the future. Additionally, screening for fluid status abnormalities (dehydration, anemia, etc.) is recommended through routine lab work as these abnormalities would make this finding more prevalent. The aortic root is mildly dilated; however, the reported blood pressure is normal and simple monitoring is advised. No significant valvular insufficiencies were noted, and no structural issues identified.

Prognosis is good.



**PATIENT**

Bella Triompo

**SPECIES**

Canine

**BREED**

Labrador Mix

**SEX**

Female Spayed

**AGE**

11 years

**WEIGHT**

71.2lbs

**INTERPRETED BY**

Maggie Machen  
 Lamy, DVM  
 DACVIM (Cardiology)

**IMAGING PERFORMED BY**

Pamela Harrigan,  
 RDCS

**HOSPITAL NAME**

Wignall Animal  
 Hospital

**REFERRING VET**

Dr. Colella

**INVOICE**

25715

**DATE**

8/11/22

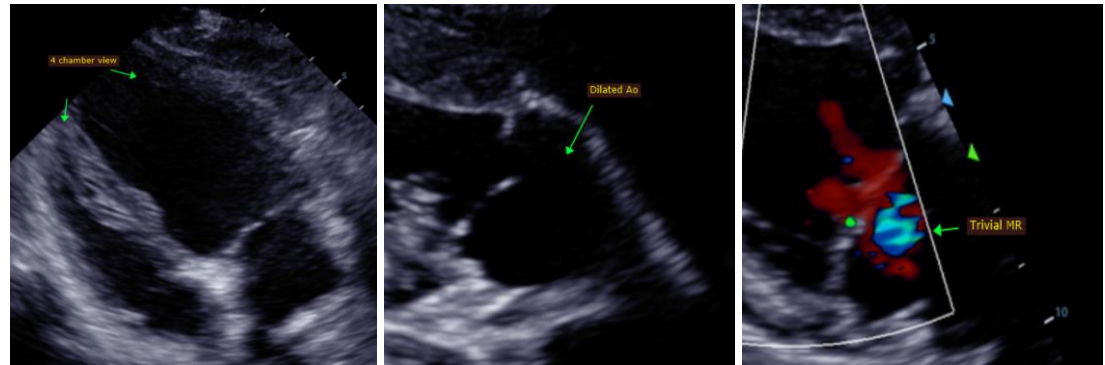
**RECOMMENDATIONS**

- No cardiac medications are indicated.
- Baseline lab work recommended if not recently performed.
- No cardiac contraindication for general anesthesia.
- Monitor for development of a cough, labored breathing, exercise intolerance or collapse episodes.

**PLAN**

Recommend recheck echocardiogram in 12-18 months to screen for progression or development of concurrent cardiac disease that the preexisting murmur may mask.

**IMAGES**



The information and recommendations provided are based on the images presented by the referring veterinarian. No evaluation can be communicated regarding pathology that was not visible in the image/video clips provided.

Thank you for this referral. This report was generated using transcription software, and minor dictation errors may be present. If the clinical or image interpretation does not parallel your findings or if I can be of any further assistance, please contact me.

**Maggie Machen Lamy, DVM**  
 Diplomate of the American College of Veterinary Internal Medicine (Cardiology)  
 info@sonopath.com